



Secondary Soft Tissue Sarcoma after Carbon Ion Radiotherapy for Sacral Chordoma

Yasuhiro Yamamoto*

Department of Orthopaedics Surgery, School of Medicine, Fujita Health University, Japan

Keywords

Chordoma; Post-radiation sarcoma; Carbon ion radiotherapy

Clinical Image

Highly malignant sarcomatoid areas rarely observed in cases of chordoma are post-radiation, sarcomatoid chordoma, dedifferentiated chordoma. In this report, we describe a case with secondary soft tissue sarcoma after carbon ion radiotherapy (CIRT) for sacral chordoma.

A 73-year-old man complained of having pain in his bottom for two years. Radiological examinations revealed a sacral tumor and histological diagnosis from a needle biopsy specimen was chordoma.

CIRT was performed for this lesion and the volume of tumor shrank remarkably (Figure1), but multiple subcutaneous tumors were seen in the subcutaneous adipose tissue in the irradiation area in five years after CIRT (Figure 2). We performed resectional biopsy for the one of them and histological diagnosis was pleomorphic sarcoma. Initially, we diagnosed dedifferentiated chordoma and its subcutaneous metastasis, and we resected the sacral bone below at the level of S2 including the pleomorphic sarcoma lesions. We concluded the secondary soft tissue sarcoma arising in the subcutaneous after CIRT for chordoma and its skip lesions because we were not able to detect the continuously of these two conditions in pathological examination.

Soft tissue sarcoma arising after CIRT for chordoma has not been reported and we should carefully follow up patients who had CIRT therapy.

OPEN ACCESS

***Correspondence:**

Yasuhiro Yamamoto, Department of Orthopaedics Surgery, School of Medicine, Fujita Health University, Japan,
E-mail: yyasuhiro88jp@yahoo.co.jp

Received Date: 09 Oct 2017

Accepted Date: 23 Nov 2017

Published Date: 05 Dec 2017

Citation:

Yamamoto Y. Secondary Soft Tissue Sarcoma after Carbon Ion Radiotherapy for Sacral Chordoma. *Clin Oncol.* 2017; 2: 1385.

Copyright © 2017 Yasuhiro

Yamamoto. This is an open access article distributed under the Creative Commons Attribution License, which permits unrestricted use, distribution, and reproduction in any medium, provided the original work is properly cited.

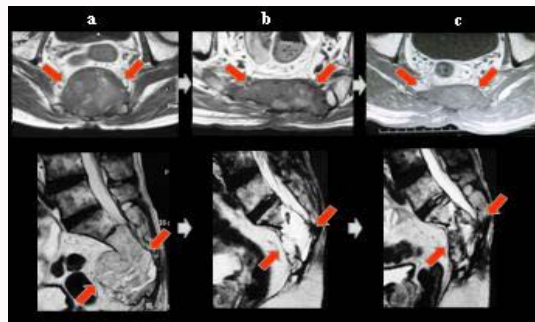


Figure 1: a: Before CIRT. A T2-weighted image on examination demonstrated large sacral chordomainvasing up to S2; b: 3 years after CIRT; c: 5 years afret CIRT.

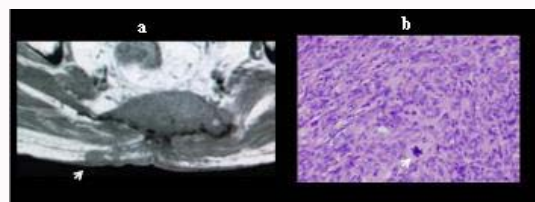


Figure 2: a: A T1-weighted image on MRI examination demonstrated a subcutaneous tumor having a diameter of 1.5 cm (white arrow). b: Resectional biopsy was performed. A high-grade pleomorphic sarcoma with atypical mitosis is present (white arrow). (white bar, 50µm).