



Diagnostic Accuracy of Technetium-99m -Octreotide in Imaging Neuroendocrine, Our Experience with Literature Review

Naima Al Bulushi^{1*}, Badriya Al Saqri¹, Marwa Al Amri¹, Aymen Al Hadid², Hafidh Al Jahdami¹, Mohammed Al Zadjali³ and Mimouna Al Risi³

¹Royal Hospital, Ministry of Health, Oman

²Oman Medical Specialty Board (OMSB), Oman

³Medical students, College of Medicine, Sultan Qaboos University Hospital, Oman

Abstract

Purpose: The aim of this observational cross-sectional study with retrospective review of the data is to evaluate the efficacy of using Technetium-99m - Octreotide in imaging Neuroendocrine tumors (NETs).

Materials and Methods: A total of 58 patients with Technetium-99m -Octreotide (Tc-99m- OCT) were identified in our database, from January 2013 until December 2016. 41 patients (age range of 15-75 year) meet our inclusion criteria namely; histopathology proven neuroendocrine tumors, Technetium-99m -Octreotide scan, CT, MRI or both done in our institute for correlation.

Results: 23 patients had true positive Tc-99m- OCT scan. In addition to the primary tumors the Octreotide scan revealed metastasis in the lung, liver and retroperitoneal lymph nodes. The smallest lesion detected on Octreotide scan was a 4-mm pulmonary nodule, that was missed on lung window CT scan. The Tc-99m- OCT had 17 true negative, one false negative and no false positive. The CT and MRI scans had 18 true positive, 17 true negative, 5 false negative and one false positive. The overall sensitivity, specificity, accuracy, positive and negative predictive values of Tc-99m- OCT scan were; 96%, 100%, 97%, 100% and 94% respectively. Whereas those of CT and MRI were; 78%, 94%, 85%, 94% and 77%, respectively.

Conclusion: The overall diagnostic accuracy of Technetium-99m-Octreotide is high. In addition to the conventional radiological investigations, Tc-99m-OCT scan is a mandate for better and accurate staging of patients with NETs.

Keywords: Neuroendocrine tumors; Somatostatin; Technetium-99m; Indium-111; Octreotide; Gallium-68

Introduction

Neuroendocrine tumours (NET) are uncommon type of tumors arising from the epithelial tissue of the neuroendocrine system [1]. They can be either functioning or non-functioning type depending on the presence or absence of hormone and peptide secretions from the tumors. There are about 40-50 cases per million habitants which accounts for 0.5% of all adult cancers [1]. The NET form 2% - 4% of the adults with Cancer of Unknown Primary (CUP) [2,3]. Identifying the primary tumor in patients with NETs, is crucial in the management of those patients even in the advanced stages with metastasis. Studies showed that resecting the primary tumor improves the quality of life and the overall survival in patients with NET even with metastatic disease [4,5].

As the NETs have increased density of somatostatin receptors (SSTRs), it was possible to visualize those tumors with radiolabeled somatostatin analogues. The imaging of NETs and other tumors with positive SSTRs started more than two decades back using Indium-111-DTPA-[D-Phe¹]-Octreotide (In-111-OCT) [6]. However, because the somatostatin analogue is labeled with Indium-111 this enforced some limitations such as limited availability, high cost, higher radiation burden to the patient and the overall suboptimal image quality [7]. One and a half decade back Decristoforo et al. [8] described the development of a Tc-99m-labeled somatostatin analogue [Tyr³-octreotide (TOC) and hydrazinonicotinic acid (HYNIC)]. In their study, they found that Tc-99m-

OPEN ACCESS

*Correspondence:

Naima Al Bulushi, Nuclear Medicine Department and Molecular Imaging Centre, Royal Hospital, P.O. BOX 1331, P.C:111 Muscat International Airport, Oman,

E-mail: nkd004@hotmail.com

Received Date: 26 Sep 2017

Accepted Date: 23 Oct 2017

Published Date: 24 Oct 2017

Citation:

Al Bulushi N, Al Saqri B, Al Amri M, Al Hadidi A, Al Jahdami H, Al Zadjali M, et al. Diagnostic Accuracy of Technetium-99m -Octreotide in Imaging Neuroendocrine, Our Experience with Literature Review. Clin Oncol. 2017; 2: 1361.

Copyright © 2017 Naima Al Bulushi. This is an open access article distributed under the Creative Commons Attribution License, which permits unrestricted use, distribution, and reproduction in any medium, provided the original work is properly cited.

Table 1: Demographic details of the patients with the histopathology of the lesions post-surgery.

No	Sex	Age	Histopathology
1	M	72	Colon NET
2	M	36	Poorly differentiated NET of duodenum
3	M	26	Pancreatic Insulinoma
4	F	28	Paraganglioma
5	F	31	Medullary thyroid cancer
6	M	39	Metastatic malignant NET with no known primary
7	M	30	Pancreatic Insulinoma
8	F	28	Paraganglioma
9	F	33	Medullary thyroid cancer
10	M	41	MEN1 with Pancreatic NET
11	F	26	MEN 1 with Pancreatic Islet cell tumors
12	F	63	Endobronchial NET
13	M	41	Gastric gastrinomas & Pancreatic Islet cell tumor
14	M	66	Poorly differentiated gastric NET
15	F	47	MEN 1 with multiple NETs in Stomach, duodenum and pancreas
16	M	53	NET of the lung
17	M	41	Pheochromocytoma of pancreas
18	F	29	Metastatic NET with no known primary
19	F	53	Gastric NET
20	F	72	Carcinoid tumor of ileum
21	F	58	Carcinoid tumor of Colon
22	M	33	Endobronchial Carcinoid tumor
23	M	60	Metastatic NET
24	M	39	Pancreatic NET
25	M	41	Pancreatic Insulinoma
26	F	26	Paraganglioma
27	M	43	Appendix NET
28	F	17	Appendix Carcinoid
29	M	31	Appendix Carcinoid
30	F	15	Appendix NET
31	F	53	Gastric Carcinoid
32	M	59	Mesenteric Carcinoid
33	F	58	Small bowel NET
34	M	12	left lobe bronchus Carcinoid
35	F	72	Small bowel NET
36	M	41	Pancreatic NET
37	F	60	Gastric NET
38	M	68	Colon NET
39	F	17	Lung Carcinoid
40	M	43	Appendix NET
41	F	25	Appendix Carcinoid

NET: Neuroendocrine tumor; MEN: Multiple endocrine neoplasia

TOC had high tumor to back ground ratio and optimal imaging time, which was done as one-day protocol as appose to the two days' protocols (4 and 24 hours imaging) for In-111-OCT. with the advent of PET/CT more positron emitting radiotracers were used to image the NETs, those include F-18-FDG followed by F-18-FDOPA [9].

However, Ga-68-DOTA-peptide PET/CT was found to be the most useful in imaging NETs including visualization, initial staging and detection of relapse [10]. It is also used to select patients who are likely to benefit from molecular radiotherapy i.e., Peptide Receptor Radionuclide Therapy (PRRT), which consists of administration of radio-therapeutic Yttrium-90 (Y-90) or Lutetium-177 (Lu-177) versions of the same peptides used for imaging of inoperable NET [10]. However, the latter is not readily available, hence most of patients with NETs were scanned and operated based on the findings on multidetector computed tomography (MDCT) and Magnetic Resonance Imaging (MRI) only.

Materials and Method

Patients

We introduce Technetium-99m instead of Indium-111 labeled Octerotide in the last quarter of 2012. In our data base, there were 58 patients who had Tc-99m- OCT scans done between January 2013 and December 2016. 41 patients meet our inclusion criteria; that were histopathology proven somatostatin positive tumors, biochemical evidence of somatostatin tumors, Technetium-99m labeled Octreotide scan, CT and MRI. They were 21 males and 20 females with age range of 15-75 years (mean age of 42.7 years) Table 1. The findings on the Tc-99m-OCT scans were correlated lesion by lesion to the available MDCT and MRI scans.

Patients preparations

The patient should be off somatostatin receptor blocking agents for 72 hours prior to the study. Occasionally, patients will be studied on somatostatin agents to assess the degree of suppression of uptake in a known lesion. In addition, the patients are advised to be on a liquid diet for two days before the scan with a mild laxative to be taken the evening before. On the day of the scan the patient should fast until the end of the first scan, but should be well hydrated. For breast feeding mothers, they need to stop breast feeding 12 Hrs post Tc-99m-OCT injection [11].

Preparation Technetium-99m- labeled Octreotide

The Tc-99m-OCT is prepared as per the instructions attached to the product kit. The Octreotide kit consist of two vials; vial (1) which contains 20 micrograms of Hynic- Tyr-Octreotide.TFA and vial (2) which contains 10 microgram (EDDA) as a stabilizing Re-agent. The preparation starts by placing vial (1) in a suitable lead shielded container. This is followed by dissolving the content of vial (2) (EDDA) in 1 ml of saline and shaking it gently. Following that 0.5 ml from vial (2) (EDDA) is injected to vial (1) Hynic- Tyr-(Octreotide). This step is followed by gentle shaking to dissolve the content of vial (1). 1ml of Tc-99m-sodium pertechnetate from the elution, which should be 2200 MBq (59.45 mCi), is injected to vial (1). The reconstituted vial (1) Hynic- Tyr-(Octreotide) is then placed on the dry heater block which should is set at 80° degree. The vial should be boiled for 20 minutes using a breathing needle. The reconstituted vial is left to cool down at room temperature for 30 min. The radiopharmaceutical Tc-99m-Hynic-Tyr-(Octreotide) should be used within 6 hours.

Technetium-99m - Octreotide scan

The dose used for adult patients is 740 MBq (20 mCi) Tc-99m-Octreotide and the whole body and static images are done at two and four hours' post radiotracer injection. The whole-body scan is performed using dual head gamma camera, using image matrix of 256 x 1024 with speed of 8 cm/min and 5 minutes for the each static image. The SPECT images are performed for the region of interest, as

Table 2: Comparison between the Tc-99m-OCT scan, CT&MRI scan results.

	TP	TN	FP	FN
OCT scan	23	17	-	1
CT and MRI	18	17	1	5

OCT scan: Technetium-99m-Octerotide Scan; CT: Computed Tomography; MRI: Magnetic Imaging Resonance.

requested by the nuclear medicine physician, using 128 x 128 matrix, 1.45 zoom and 30 seconds per view for 32 frames.

This study was approved by the Ethics and research committee in our institution (MESRC-11/2015).

Results

Out of the 41 patients who were included in this study, 23 showed single or multiple Tc-99m-OCT avid lesions. Most of our patients had either NET, some were known or with strong family history of multiple neuroendocrine neoplasms (MEN) subtype I or II. Others had specific type of NET such as carcinoid tumors of bowel or bronchus, medullary thyroid cancer, islet cell tumors and pheochromocytoma, (Table 1).

The Tc-99m-OCT showed true positive results in 23 patients, whereas the CT and MRI showed true positive results in 18 patients. The Tc-99m-OCT showed one false negative result in a patient with incidental finding of left retroperitoneal mass, the histopathology of which was a well differentiated paraganglioma. The CT and MRI on the other hand showed false positive result in 1 patient with carcinoid tumor of the appendix and few mesenteric lymph nodes and the patient was upstaged metastatic disease. The Tc-99m-OCT scan was performed to confirm the CT findings, but it showed no uptake in the mesenteric lymph nodes, on 6 months' follow-up CT scan the mesenteric lymph nodes resolved and the patient remained disease free after 2 years of follow-up. Also the CT and MRI showed false negative results in 5 patients, in which the TC-99m-OCT scan detected metastasis in the bones, lung and retroperitoneal lymph nodes, resulting in upstaging of those patients. (Table 2).

The Octreotide scan SN, SP, PPV and NPV were 96%, 100%, 100% and 94% respectively. On the other hand, the SN, SP, PPV and NPV of the CT and MRI were 78%, 94%, 94%, 77% respectively. The Tc-99m-OCT showed significantly higher sensitivity and negative predictive value compared to those of CT and MRI. However, the specificity and positive predictive values of CT and MRI were not significantly lower than those of Tc-99m-OCT scan.

One of the patients in this cohort was 47 years old female who is known to have multiple endocrine neoplasia type 1 (MEN 1). She presented with severe diarrhoea and she was investigated for NET. The post contract CT scan of the abdomen and pelvis revealed no abnormality apart for a small, 7 mm, benign looking preduodenal lymph node. She then had Tc-99m-Octreotide scan which revealed focal uptake in the preduodenal lymph node and intense uptake in the proximal small bowel, Figure 1. For further confirmation, the patient was sent abroad for Gallium-68-DOTA scan which revealed intense abnormal uptake in the stomach, duodenum, pancreas and preduodenal lymph node. The patient underwent Whipple's procedure and the histopathology report came as multiple gastrinomas in the stomach, duodenum, pancreas and one preduodenal metastatic lymph node. In a second patient, who was 72 years old male with known NET of the colon with single metastasis to the liver, the post contrast CT scan of chest and abdomen showed the known metastatic

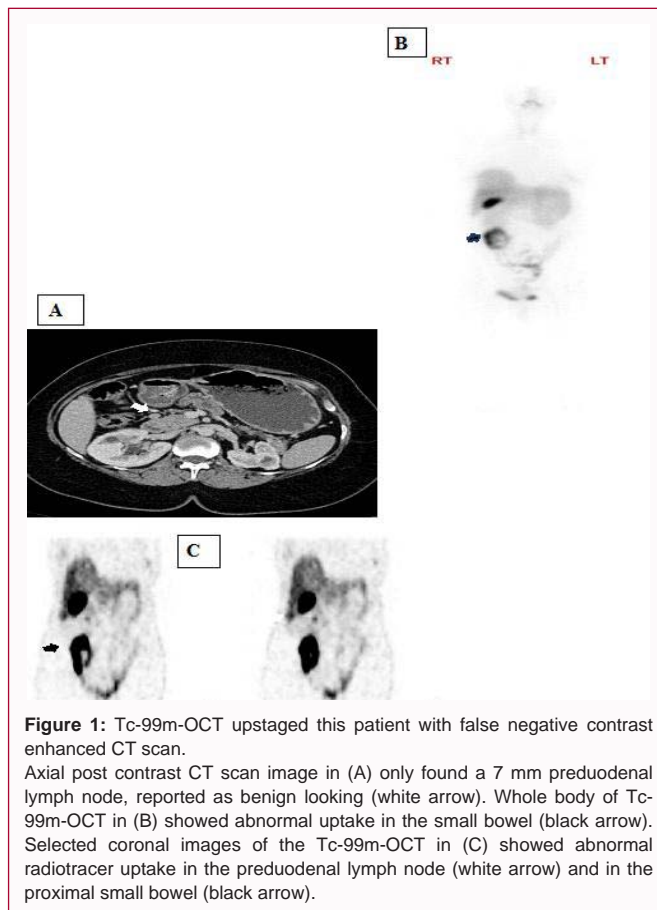


Figure 1: Tc-99m-OCT upstaged this patient with false negative contrast enhanced CT scan. Axial post contrast CT scan image in (A) only found a 7 mm preduodenal lymph node, reported as benign looking (white arrow). Whole body of Tc-99m-OCT in (B) showed abnormal uptake in the small bowel (black arrow). Selected coronal images of the Tc-99m-OCT in (C) showed abnormal radiotracer uptake in the preduodenal lymph node (white arrow) and in the proximal small bowel (black arrow).

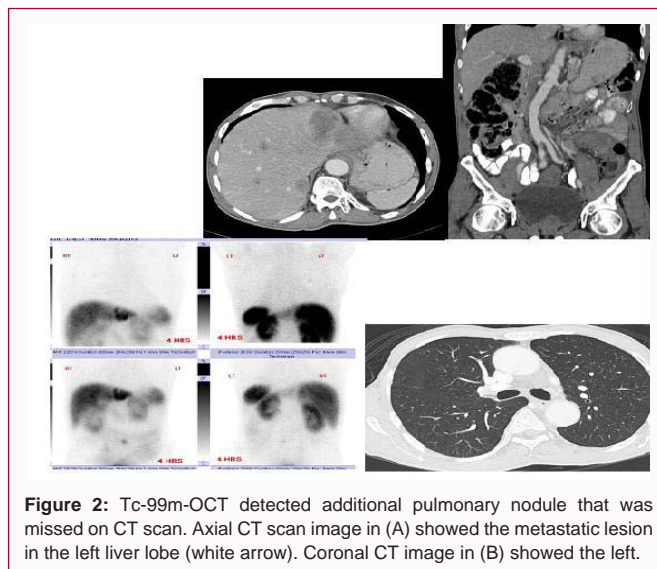


Figure 2: Tc-99m-OCT detected additional pulmonary nodule that was missed on CT scan. Axial CT scan image in (A) showed the metastatic lesion in the left liver lobe (white arrow). Coronal CT image in (B) showed the left.

lesion in the liver with a small, 9 mm, mesenteric lymph node of query significance. The Tc-99m-Octreotide scan showed Octreotide avid lesion in the liver, focal uptake in the mesenteric lymph node and a small, 4 mm, Octreotide avid lung nodule that was overlooked in the CT scan as it was solitary and small, denoting additional metastatic foci and changing the surgical management in this patient, (Figure 2). Another patient who was 29 years old female known as MEN1, and the post contrast CT scan showed pancreatic lesion. The Octreotide scan upstaged this patient by showing additional foci of Octreotide avid lesions in the right breast and left distal femur in addition to

the known lesion in the pancreas. Additional examples of Octreotide scan upstaging the patients was in a 33 years old female, known to have medullary thyroid cancer. Post contrast CT chest, that was done as part of the disease surveillance, showed left sided cervical lymph nodes only. However, the Octreotide scan showed the uptake in the cervical lymph nodes in addition to focal uptake in the left clavicle. Reviewing the CT images revealed that there was a destructive lesion involving the distal aspect of the right clavicle, as this was at the tip of the field of view, it was overlooked on the CT.

Discussion

Somatostatin is a peptide hormone made of 14 amino acids, it is normally found in the cerebral cortex, hypothalamus, brain stem, gastrointestinal tract and in the pancreas [6]. To date there are five known subtypes of Somatostatin receptors (SSTR) that are expressed in various levels in NETs, SSTR 2 & 5 are the commonest with their frequency of expression in the NET ranging from 70% – 90% [12]. Octreotide is the first somatostatin known analogue, it is SSTR subtype 2 receptor agonists [13,14]. Somatostatin receptor (SSR) imaging is used for; gastrointestinal and brain tissues evaluation, neuroendocrine tumors (NET), lung cancer, meningioma and lymphoma. In addition, it is used prior to Peptide Receptor Radionuclide Therapy (PRRT).

For decades radiolabeled somatostatin analogue, DTPA-[D-Phe¹]-Octreotide) was used in imaging NET [6]. However, in our study, we replaced the traditionally used radioisotope, Indium-111 (In-111) by Technetium 99m (Tc-99m). Using Tc-99m instead of In-111 solved the issues of availability as the Octreotide is readily available as a cold kit in our department. Hence, it is labeled with Tc-99m whenever it's needed. It is also much cheaper than buying the In-111-labelled Octreotide and the overall image quality with Tc-99m is much better than those with In-111. In both Tc-99m & In-111 labeled Octreotide, the spleen is the highest exposed organ (the critical organ). The estimated absorbed dose of the spleen with Tc-99m-OCT in mGy/MBq is 0.030 [15] and that of In-111-OCT is 0.665 [16]. The risk-weighted equivalent dose to whole body or "effective dose" is measured in (mSv/MBq). The effective dose of Tc-99m-OCT is much less than that of In-111-OCT, 0.0056 [15] and 0.117 [16] respectively (Table 2). In addition, Gamma Exposure rate at 1 cm from 1 mCi of Tc-99m is 720 mR/hr and that of In-111 is 3200 mR/h, i.e. the exposure of the workers from the In-111 is 4.4 times that of Tc-99m.

When comparing lesion by lesion detected by Tc-99m-OCT to those detected by MDCT and MRI, the Octreotide study could detect all lesion except one, which was a well differentiated paraganglioma. The Sensitivity of Octreotide in detecting NET was higher than that of MDCT and MRI (96% vs. 78%). The Octreotide showed more lesions than MDCT and MRI which upstaged the patients and changed the management.

Reviewing the literature for Tc-99m-OCT, there were very few papers available and the number of patients in this paper might be the largest mentioned in the literature so far. In the last decade, many centers shifted from conventional scintigraphy imaging for NET using In-111 /Tc-99m labeled Octreotide to PET/CT, particularly after the advent of Ga-68-DOTA peptides. Studies have shown the superiority of Ga-68-DOTA peptide PET/CT imaging over conventional SRS [17]. In a study that included one hundred nine patients with gastro-entero-pancreatic NETs, Ga-68-DOTA-NOC PET/CT showed sensitivity and specificity of 78.3% and 92.5%,

respectively, for primary tumor and 97.4% and 100% for metastases. It was better than a conventional imaging modality for the detection of both primary tumor ($p < 0.001$) and metastases ($p < 0.0001$). It changed the management strategy in 21 patients (19%) and supported management decisions in 32 patients (29%) [18].

Reasons for the preference of using Ga-68-DOTA include easy and economical synthesis of peptides which does not require a cyclotron unlike ¹¹¹In. Another important factor is the less imaging time (2 h for Ga-68-DOTA peptides, instead of the 4 plus 24 h acquisition for In-111). When compared to the Tc-99m-OCT, both are imaged within 2 hours, however PET has higher spatial resolution compared to the single photon emission computed tomography (SPECT) (3 mm - 6 mm versus 10 mm - 15 mm). Although in our study the smallest lesion detected was 4 mm lung nodule, the Tc-99m-OCT missed multiple small lesions in the stomach and pancreas that were detected by Ga-68-DOTA PET/CT scan. In addition, DOTA-peptides have higher and broader affinity for SSTRs compared to Octreotide. Finally, tracer uptake quantification in the region of interest can be achieved using PET [17].

Conclusion

In staging and follow-up patients with NETs, Somatostatin receptor imaging (SSRT) is a mandate for better and accurate staging as well assessing the avidity of the primary tumor for future follow-up. In this study, we showed that the sensitivity and negative predictive values of Tc-99m-OCT scan is significantly higher than that of CT and MRI.

Using Tc-99m instead of In-111 had several advantages that include better availability, cheaper and higher quality images. In addition, to less radiation exposure to both patients and nuclear medicine personnel. The introduction of PET imaging with ⁶⁸Ga and its labelling with DOTA compounds has cleared the way for somatostatin receptor imaging with a viable PET agent, with all the advantages compared to single photon imaging. This has revolutionized the current and future clinical practice for NET [19]. The main limitation of the study is a retrospective data collection and hence all the patients included were known to have NETs, in addition, to the small sample size.

References

1. Plöckinger U, Rindi G, Arnold R, Eriksson B, Krenning EP, de Herder WW, et al. Guidelines for the diagnosis and treatment of neuroendocrine gastrointestinal tumours: a consensus statement on behalf of the European Neuroendocrine Tumour Society (ENETS). *Neuroendocrinology*. 2004; 80(6): 394–424.
2. Kwekkeboom DJ, Krenning EP, Lebtahi R, Komminoth P, Kos-Kudła B, de Herder WW, et al. ENETS consensus guidelines for the standards of care in neuroendocrine tumors: peptide receptor radionuclide therapy with radiolabeled somatostatin analogs. *Neuroendocrinology*. 2009; 90(2): 220–226.
3. Öberg K, Castellano D. Current knowledge on diagnosis and staging of neuroendocrine tumors. *Cancer Metastasis Rev*. 2011; 30(suppl): 3–7.
4. Rothenstein J, Clearly SP, Pond GR, Dale D, Gallinger S, Moore MJ, et al. Neuroendocrine tumors of the gastrointestinal tract: a decade of experience at the Princess Margaret Hospital. *Am J Clin Oncol*. 2008; 31(1): 64–70.
5. Abbruzzese JL, Abbruzzese MC, Lenzi R, Hess KR, Raber MN. Analysis of a diagnostic strategy for patients with suspected tumors of unknown origin. *J Clin Oncol*. 1995; 13(8): 2094–2103.
6. Sandler MP, Coleman RE, Patton JA, et al. *Diagnostic Nuclear Medicine*.

- 4th ed. LWW, 2003. P 734.
7. Bluma Linkowski Faintuch, Nilda Petrona Sosa Pereira, Solomon Faintuch II, Emiko Muramoto I, Constancia Pagano Gonçalves Silva. Lanreotide and octreotide complexed with technetium-99m: labelling, stability and biodistribution studies. *Brazilian Journal of Pharmaceutical Sciences*. 2004; 40(1).
 8. Decristoforo C, Melendez-Alafort L, Sosabowski JK, Mather SJ. 99mTc-HYNIC-[Tyr3]-octreotide for imaging somatostatin-receptor-positive tumors: preclinical evaluation and comparison with 111In-octreotide. *J Nucl Med*. 2000; 41(6): 1114-1119.
 9. Imperiale A, Rust E, Gabriel S, Detour J, Goichot B, Duclos B, et al. 18F-Fluorodihydroxyphenylalanine PET/CT in Patients with Neuroendocrine Tumors of Unknown Origin: Relation to Tumor Origin and Differentiation. *J Nucl Med* 2014; 55(3): 367-372.
 10. Banerjee SR, Pomper MG. Clinical Applications of Gallium-68. *Appl Radiat Isot*. 2013; 0: 2-13.
 11. Stabin MG, Breitz HB. Breast Milk Excretion of Radiopharmaceuticals: Mechanisms, Findings, and Radiation Dosimetry. *J Nucl Med*. 2000; 41(5): 863-873.
 12. Papotti M, Bongiovanni M, Volante M, Allia E, Landolfi S, Helboe L, et al. Expression of somatostatin receptor types 1-5 in 81 cases of gastrointestinal and pancreatic endocrine tumors: a correlative immunohistochemical and reverse-transcriptase polymerase chain reaction analysis. *Virchows Arch*. 2002; 440: 461-475.
 13. Schmid HA Schoeffter P. Functional activity of the multiligand analog SOM230 at human recombinant somatostatin receptor subtypes supports its usefulness in neuroendocrine tumors. *Neuroendocrinology*. 2004; 80 Suppl 1: 47-50.
 14. Schmid HA. Pasireotide (SOM230), development, mechanism of action and potential applications. *Mol. Cell. Endocrinol*. 2008; 286(1-2): 69-74.
 15. Grimes J, Celler A, Birkenfeld B, Shcherbinin S, Listewnik MH, Piwowarska-Bilska H, et al. Patient-Specific Radiation Dosimetry of 99mTc-HYNIC-Tyr3-Octreotide in Neuroendocrine Tumors. *J Nucl Med*. 2011; 52(9): 1474-1481.
 16. Krenning EP, Bakker WH, Kooij PP, Breeman WA, Oei HY, de Jong M, et al. Somatostatin Receptor Scintigraphy with Indium-111-DTPA-D-Phe-1-Octreotide in Man: Metabolism, Dosimetry and Comparison with Iodine-123-Try-3-Octreotide. *J Nucl Med*. 1992; 33(5): 652-658.
 17. Sharma P, Singh H, Bal C, Kumar R. PET/CT imaging of neuroendocrine tumors with 68Gallium-labeled somatostatin analogues: An overview and single institutional experience from India. *Indian J Nucl Med*. 2014; 29(1): 2-12.
 18. Naswa N, Sharma P, Kumar A, Nazar AH, Kumar R, Chumber S, et al. Gallium-68-DOTA-NOC PET/CT of Patients With Gastroenteropancreatic Neuroendocrine Tumors: A Prospective Single-Center Study. *AJR Am J Roentgenol*. 2011; 197(5): 1221-1228.
 19. Al-Nahas A, Win Z, Szyszko T, Singh A, Nanni C, Fanti S, et al. Gallium-68 PET: a new frontier in receptor cancer imaging. *Anticancer Res*. 2007; 27(6B): 4087-4094.