



Laparoscopic Technique and Safety Experience with Barbed Suture Closure in Permanent Stoma through the Abdominal Wall Route

Nobuhisa Matsuhashi, Takao Takahashi, Toshiyuki Tanahashi, Satoshi Matsui, Hisashi Imai, Yoshihiro Tanaka, Kazuya Yamaguchi and Kazuhiro Yoshida*

Department of Surgical Oncology, Gifu University School of Medicine, Gifu City, Japan

Background

We present our initial experience of intracorporeal closure of between abdominal wall and elevated sigmoid colostomy with totally laparoscopic APR.

Introduction

Recently, several reports on laparoscopic surgery with abdominoperineal resection (APR) for rectal cancer have been published [1,2]. In general, APR of stoma was performed by sigmoid colon. The sigmoid colostomy is usually performed through a retroperitoneal route, which is theoretically favourable for preventing postoperative parastomal hernia formation and intestinal obstruction in conventional open surgery. But a retroperitoneal route is difficulty for technically in laparoscopic surgery. Therefore, when the colostomy is performed by elevated through the abdominal wall directly, the intestinal obstruction often occur between abdominal wall and elevated sigmoid colostomy. In our initial experience, we introduce a knotless, unidirectional, barbed suture to the intracorporeal closure of between abdominal wall and elevated sigmoid colostomy with laparoscopic APR (Figure 1a and b). This method with the V-Loc[®] suture indicated that surturing technique is only required and a special technique isn't required with the V-Loc[®].

Discussion

The V-Loc[®] 180 closure device is a unidirectional barbed variant of the absorbable copolymer polyglyconate (Maxon; Covidien Mansfield, MA, USA) and has the same material and degradation properties as Maxon (monofilament polyglyconate) suture. 3-0 V-Loc[®] suture has the same tensile strength as 3-0 Maxon. A loop at the end of the suture can be used for knotless suturing, and the first 2 cm of the suture are without barbs to allow throws to be readjusted before the barbs are engaged (Figure 2).

OPEN ACCESS

*Correspondence:

Kazuhiro Yoshida, Department of Surgical Oncology, Gifu University School of Medicine, 1-1 Yanagido Gifu City 501-1194, Japan, Tel: +81-58-230-6233; Fax: +81-58-230-1074; E-mail: kyoshida@gifu-u.ac.jp

Received Date: 14 Sep 2017

Accepted Date: 21 Aug 2017

Published Date: 25 Sep 2017

Citation:

Matsuhashi N, Takahashi T, Tanahashi T, Matsui S, Imai H, Tanaka Y, et al. Laparoscopic Technique and Safety Experience with Barbed Suture Closure in Permanent Stoma through the Abdominal Wall Route. *Clin Oncol.* 2017; 2: 1350.

Copyright © 2017 Kazuhiro

Yoshida. This is an open access article distributed under the Creative Commons Attribution License, which permits unrestricted use, distribution, and reproduction in any medium, provided the original work is properly cited.

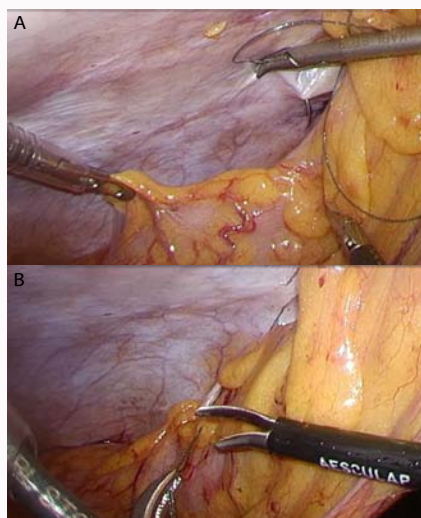


Figure 1a and b: Intra-abdominal view showed with intracorporeal closing of between abdominal wall and elevated sigmoid colostomy by the V-Lock.



Figure 2: A total of 15 cm of 3-0 V-Loc 180 suture on a V-20 needle (26 mm tapered).

Lee et al. [3-5] first reported the incorporation of a knotless, unidirectional, barbed suture into the staple conserving technique for delta-shaped gastroduodenostomy after laparoscopic distal gastrectomy in the domain of digestive surgery. In the domain of laparoscopic colorectal surgery, we reported first a knotless, unidirectional, barbed suture to the intracorporeal closure of the pelvic cavity with laparoscopic APR [7]. In this report, we introduce a knotless, unidirectional, barbed suture to the intracorporeal closure of between abdominal wall and elevated sigmoid colostomy with laparoscopic APR.

Conclusions

In conclusion, the impact of this new closure device on laparoscopic colorectal surgery use of the knotless, unidirectional, barbed suture appears to be safe, feasible, and efficacious for intracorporeal closure of between abdominal wall and elevated sigmoid colostomy with laparoscopic APR. In the future, we expect that use of the V-Loc[®] will reduce intra-operative stress on the endoscopic colorectal surgeon.

References

1. Sackier JM, Berci G, Hiatt JR, Hartunian S. Laparoscopic abdominoperineal resection of the rectum. *Br J Surg.* 1992; 79: 1207-1208.
2. Ng SSM, Leung KL, Lee JFY, Yiu RYC, Li JCM, Teoh AYW, et al. Laparoscopic-Assisted Versus Open Abdominoperineal Resection for Low Rectal Cancer: A Prospective Randomized Trial. *Ann Surg Oncol.* 2008; 15(9): 2418-2425.
3. Lee SW, Nomura E, Tokuhara T, Kawai M, Matsuhashi N, Yokoyama K, et al. Laparoscopic technique and initial experience with knotless, unidirectional barbed suture closure for staple-conserving, delta-shaped gastroduodenostomy after distal gastrectomy. *J Am CollSurg.* 2011; 213: 39-45.
4. Lee SW, Tanigawa N, Nomura E, Tokuhara T, Kawai M, Yokoyama K, et al. Benefits of intracorporeal gastrointestinal anastomosis following laparoscopic distal gastrectomy. *World J Surg Oncol.* 2012; 10: 267.
5. Lee SW, Kawai M, Tashiro K, Nomura E, Tokuhara T, Kawashima S, et al. Laparoscopic gastrointestinal anastomoses using knotless barbed absorbable sutures are safe and reproducible: a single-center experience with 242 patients. *Jpn J Clin Oncol.* 2016; 46(4): 329-335.
6. Matsuhashi N, Takahashi T, Nonaka K, Tanahashi T, Imai H, Sasaki Y, et al. Laparoscopic technique and safety experience with barbed suture closure for pelvic cavity after abdominoperineal resection. *World J Surg Oncol.* 2013; 11: 115.
7. Matsuhashi N, Takahashi T, Tanahashi T, Matsui S, Imai H, Tanaka Y, et al. Safety and feasibility of laparoscopic intersphincteric resection for a lower rectal tumor. *Oncology Letter.* 2017; 10: 4142-4150.